Liver function tests

DR.LADAN GOSHAYESHI
ASSISTANT PROFESSOR OF GASTROENTEROLOGY AND HEPAOLO

CME

ACG Clinical Guideline: Evaluation of Abnormal Liver Chemistries

Paul Y. Kwo, MD, FACG, FAASLD[1], Stanley M. Cohen, MD, FACG, FAASLD[2] and Joseph K. Lim, MD, FACG, FAASLD[3]

Clinicians are required to assess abnormal liver chemistries on a daily basis. The most common liver chemistries ordered are serum alanine aminotransferase (ALT), aspartate aminotransferase (AST), alkaline phosphatase and bilirubin. These tests should be termed liver chemistries or liver tests. Hepatocellular injury is defined as disproportionate elevation of AST and ALT levels compared with alkaline phosphatase levels. Cholestatic injury is defined as disproportionate elevation of alkaline phosphatase level as compared with AST and ALT levels. The majority of bilirubin circulates as unconjugated bilirubin and an elevated conjugated bilirubin implies hepatocellular disease or cholestasis. Multiple studies have demonstrated that the presence of an elevated ALT has been associated with increased liver-related mortality. A true healthy normal ALT level ranges from 29 to 33 IU/l for males, 19 to 25 IU/l for females and levels above this should be assessed. The degree of elevation of ALT and or AST in the

The standard comprehensive metabolic profile panel includes:

- AST
- ALT
- alkaline phosphatase
- bilirubin
- and albumin.
- In addition, a prothrombin time may be ordered.

Aminotransferases including AST and ALT are markers of hepatocellular injury

AST

- AST is present in the liver and other organs including:
  - cardiac muscle
  - skeletal muscle
  - kidney
  - and brain

ALT

- ALT is present primarily in the liver, and thus is a more specific marker of hepatocellular cell injury
- AST increase without elevation in ALT is suggestive of cardiac or muscle disease.

ALP

- Alkaline phosphatase is found in hepatocytes on the canalicular membrane, not the bile duct cell.
- In addition to being present on the canalicular membrane of the hepatocyte, alkaline phosphatase is also found in
  - bone,
  - placenta,
  - intestine,
  - and kidney
- with the most common extrahepatic location originating from bone.

- Albumin, bilirubin, and prothrombin time are markers of hepatocellular function that can be influenced by extrahepatic factors.

- Elevations of AST and/or ALT, ALP, and bilirubin suggest hepatocellular injury and are the abnormal liver chemistries that require assessment and potential evaluation.
- A LT is a more specific marker of hepatic injury than AST.
- An elevated ALP level of hepatic origin may be confirmed by elevation of gamma-glutamyl transferase (GGT)

WHAT ARE TRULY NORMAL LIVER CHEMISTRY TESTS?

- normal ALT level ranges from :
  - **29 to 33 IU/l for males**
  - **and 19 to 25 IU/l for females,**
- and levels above this should be assessed by physicians.
- There is a linear relationship between ALT level and body mass index (BMI) that should be assessed by physicians.

- A normal ALT level may not exclude significant liver disease.
- ALT levels are higher in males than females.
- AST and ALT ULN ranges can vary between different labs.
- Clinicians may rely on local lab ULN ranges for alkaline phosphatase and bilirubin.

Before initiation of evaluation of abnormal liver chemistries,

one should repeat the lab panel and/or perform a clarifying test to confirm that the liver chemistry is actually abnormal.

(e.g., GGT if serum alkaline phosphate is elevated)

CLINICAL ASSESSMENT OF THE PATIENT WITH ABNORMAL LIVER CHEMISTRIES

- history and physical examination.
- History should include:
  - risk factors for underlying liver disease,
  - associated medical conditions
  - use of alcohol,
  - and use of medications including over-the-counter products and herbal supplements.

Prolonged period of fatigue
Itching sensation
Swelling in the lower legs
Jaundice
Getting bruised easily
Fluid build up
Development of blood vessel
Infection
Hepatic encephalopathy
Internal Bleeding
unconsciousness
Loss of appetite
High blood pressure

Palmar erythema
Terry nails
Dupuytren contracture
Spider angiomata

LFT pattern is important for DDx

HEPATOCELLULAR	CHOLESTATIC
ALT, AST > Alk Phos	**Alk Phos** > ALT, AST

**Bilirubin can be elevated in both and do not help to distinguish*

Memorial Sloan Kettering Cancer Center

PATTERNS OF LIVER CHEMISTRY TEST ELEVATIONS:

1 . **Hepatocellular injury** is defined as disproportionate elevation of AST and ALT levels as compared with the alkaline phosphatase level.

2 . **Cholestatic injury** is defined as disproportionate elevation in alkaline phosphatase level as compared with AST and ALT levels.

3 . **Mixed pattern** of injury is defined as elevation of both alkaline phosphatase and AST/ALT levels.

4 . **Isolated hyperbilirubinemia** is defined as elevation of bilirubin with normal ALP and AST/ALT levels.

- The R ratio is calculated by the formula
- **R =(ALT value÷ALT ULN)÷(alkaline phosphatase value÷alkaline phosphatase ULN)**

  - **An R ratio of >5 is defined as hepatocellular,**
  - **<2 is cholestatic,**
  - **and 2–5 is a mixed pattern.**

Table 4. Causes of elevated AST and ALT

Hepatic (generally AST>ALT)
Alcoholic liver disease
Cirrhosis (of any etiology)
Ischemic hepatitis
Congestive hepatopathy
Acute Budd-Chiari syndrome
Hepatic artery damage/thrombosis/occlusion
TPN

Hepatic (generally ALT>AST)

- NAFLD
  - Steatosis
  - NASH
- Chronic viral hepatitis
- Acute viral hepatitis
- Medications and drug-induced liver injury
  - Prescription medications
  - Herbal products and supplements
  - Over-the-counter agents
- Toxic hepatitis (amanita exposure)
- Hemochromatosis
- Autoimmune hepatitis
- Wilson's disease
- Alpha-1-antitrypsin deficiency
- Celiac disease
- Acute bile duct obstruction
- Liver trauma
- Post-liver surgery
- Veno-occlusive disease/sinusoidal obstruction syndrome
- Diffuse infiltration of the liver with cancer
- HELLP syndrome
- Acute fatty liver of pregnancy
- Sepsis
- Hemophagocytic lymphohistiocytosis

Non-hepatic

- Skeletal muscle damage/rhabdomyolysis
- Cardiac muscle damage
- Thyroid disease
- Macro-AST
- Strenous exercise
- Heat stroke
- Hemolysis
- Adrenal insufficiency

Mild/Moderate elevations in ALT/AST (patient may be asymptomatic)

- Chronic Hepatitis
- NAFLD/NASH – associated with obesity, T2DM, Hyerlipidaemia
- Metabolic liver disease - HH, WD, A1AT
- Drugs
- Autoimmune LD

Causes of a Hepatocellular Pattern of LFTs

Marked elevations in ALT/AST (patient likely to be symptomatic)

- Viral hepatitis
- Ischaemic hepatitis
- Autoimmune hepatitis
- Drug/toxins

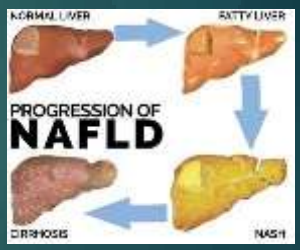

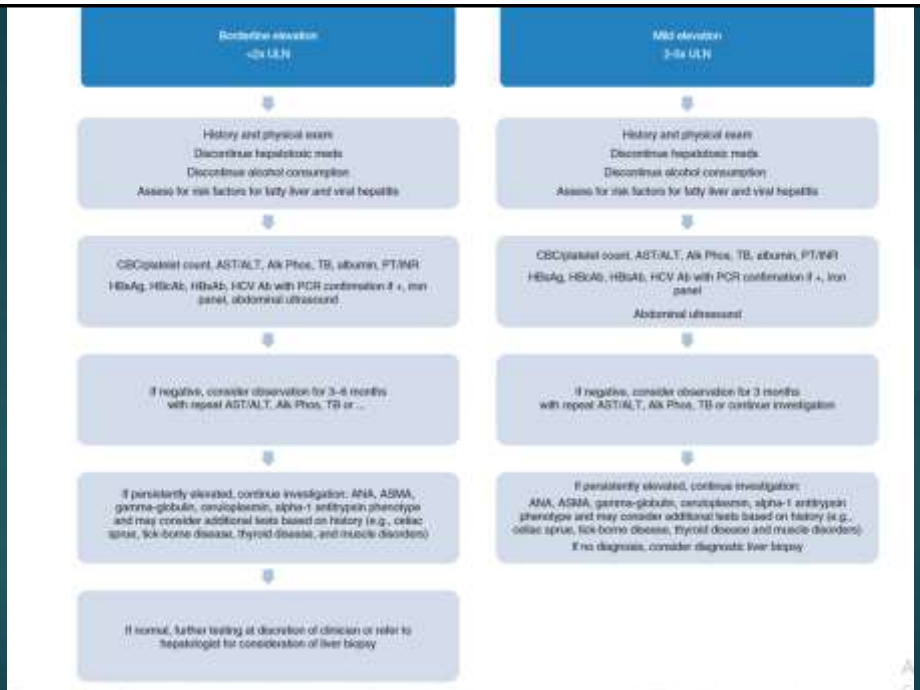

Figure 1. Algorithm for evaluation of aspartate aminotransferase (AST) and/or alanine aminotransferase (ALT) level. HCV, hepatitis C virus.

Figure 2. Evaluation of moderate elevation of aspartate aminotransferase (AST) and/or alanine aminotransferase (ALT) levels. HCV, hepatitis C virus.

Causes of a Cholestatic Pattern of LFTs

Elevated ALP and GGT ± Bilirubin, relative to transaminases

Intrahepatic (Bilirubin not elevated)

- Medications
- TPN
- Sepsis
- Postoperative
- PBC
- Alcoholic hepatitis
- Liver mets
- Pregnancy-related

Extrahepatic (Bilirubin elevated)

- Cholelithiasis (CBD)
- Malignancy
- Primary sclerosing cholangitis

GGT is useful in differentiating Liver as a cause of elevated ALP

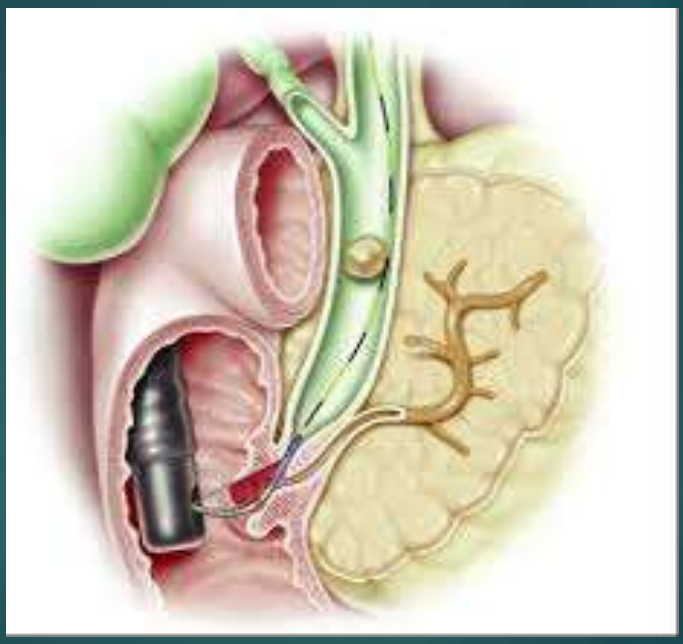

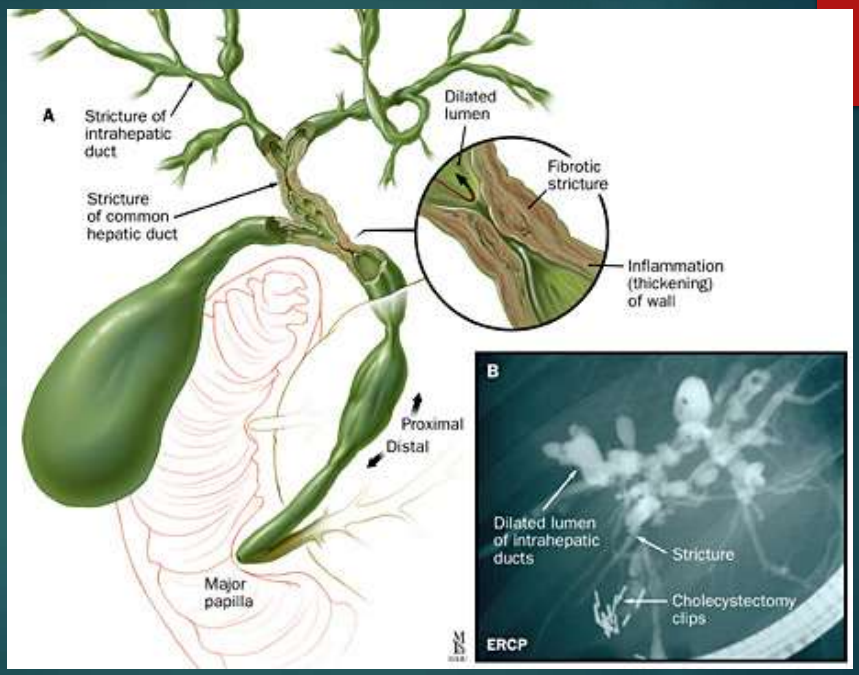
A
Stricture of intrahepatic duct
Stricture of common hepatic duct
Dilated lumen
Fibrotic stricture
Inflammation (thickening) of wall
Proximal
Distal
Major papilla
B
Dilated lumen of intrahepatic ducts
Stricture
Cholecystectomy clips
ERCP

Table 5. Causes of elevated alkaline phosphatase

Hepatobiliary
Bile duct obstruction
Choledocholithiasis
Malignant obstruction
Bile duct flukes
Bile duct stricture
Ductopenia
AIDS cholangiopathy
Cholestatic liver diseases
Primary biliary cirrhosis
PSC
Medications and drug induced liver injury
Infiltrative diseases of the liver
Sarcoid
Granulomatous hepatitis
Tuberculosis
Amyloid
Metastatic cancer
Lymphoma
Hepatic abscess
Hepatocellular carcinoma
Viral hepatitis
Cirrhosis
Vanishing bile duct syndrome
Ischemic cholangiopathy
Benign recurrent cholestasis
Sarcoidosis
Alcoholic liver disease
Intrahepatic cholestasis of pregnancy
Benign post-operative jaundice
ICU jaundice or multifactorial jaundice
TPN
Liver allograft rejection
Acute alcoholic hepatitis
Sickle cell liver crisis
Sepsis
Congestive heart failure
Hemophagocytic lymphohistiocytosis
Non-hepatic
Bone disease
Osteomalacia
Paget's disease
Primary bony malignancy
Bony metastases

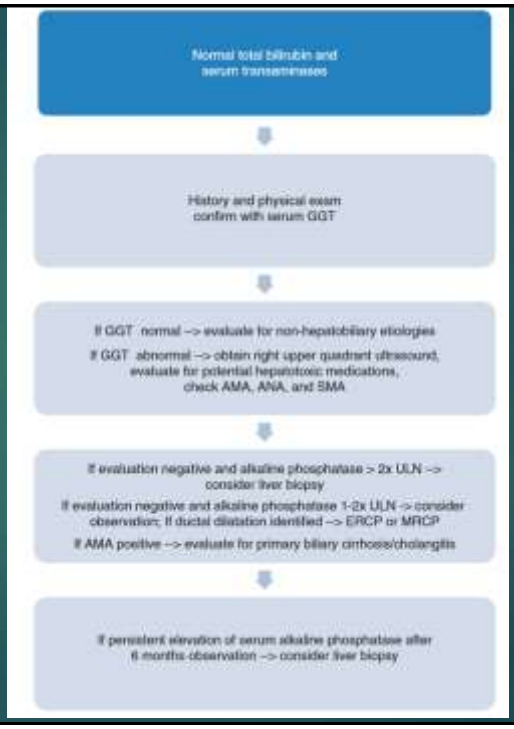

Table 6. Causes of elevated bilirubin

Elevated unconjugated bilirubin
Gilbert's syndrome
Crigler-Najjar syndrome
Hemolysis (intravascular and extravascular)
Ineffective erythropoiesis
Resorption of large hematomas
Neonatal jaundice
Hyperthyroidism
Medications
Post-blood transfusion

Elevated conjugated hyperbilirubinemia

- Bile duct obstruction
  - Choledocholithiasis
  - Malignant obstruction
  - Bile duct flukes
- Bile duct stricture
- AIDS cholangiopathy
- Viral hepatitis
- Toxic hepatitis
- Medications or drug-induced liver injury
- Acute alcoholic hepatitis
- Ischemic hepatitis

- Ischemic hepatitis
- Cirrhosis
- Primary biliary cirrhosis
- PSC
- Infiltrative diseases of the liver
  - Sarcoid
  - Granulomatous hepatitis
  - Tuberculosis
  - Metastatic cancer
  - Lymphoma
- Hepatocellular carcinoma
- Wilson disease (especially fulminant Wilson's disease)
- Autoimmune hepatitis
- Ischemic hepatitis
- Congestive hepatopathy
- Sepsis
- TPN
- Intrahepatic cholestasis of pregnancy
- Benign post-operative jaundice

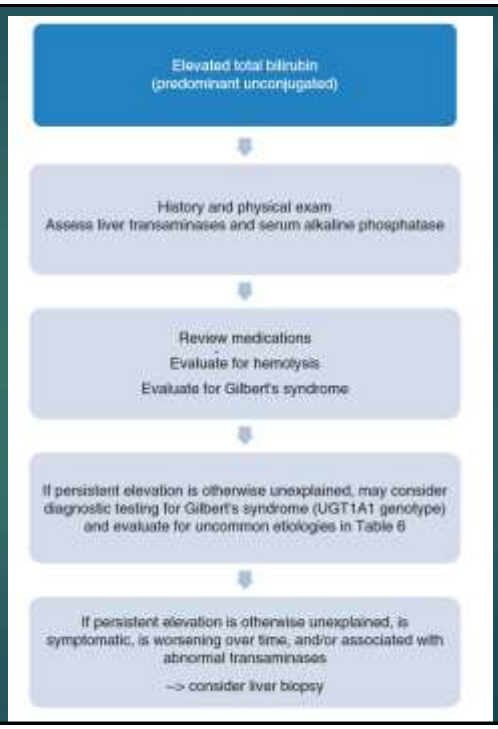
Elevated total bilirubin
(predominant unconjugated)
History and physical exam
Assess liver transaminases and serum alkaline phosphatase
Review medications
Evaluate for hemolysis
Evaluate for Gilbert's syndrome
If persistent elevation is otherwise unexplained, may consider diagnostic testing for Gilbert's syndrome (UGT1A1 genotype) and evaluate for uncommon etiologies in Table 6
If persistent elevation is otherwise unexplained, is symptomatic, is worsening over time, and/or associated with abnormal transaminases
--> consider liver biopsy

Elevated total bilirubin
(predominant conjugated)
History and physical exam
Assess liver transaminases and serum alkaline phosphatase
Review medications
Evaluate for clinically overt etiologies: sepsis, TPN, cirrhosis, and biliary obstruction
Perform right upper quadrant ultrasound
If ductal dilatation --> ERCP or MRCP
If no ductal dilatation --> check AMA, ANA, and SMA
If persistent elevation is otherwise unexplained, is symptomatic, is worsening over time, and/or associated with abnormal transaminases
--> consider liver biopsy

- 22 year old male with fatigue mild RUQ pain was refered to you
- Ast 2000
- Alt 4000
- Alp:500
- Bil t 6
- Bil d 4
- ?

- Hepatocellular pattern
- HAV IgM (+)
- Acute hepatitis A

- 60 year old man with sever RUQ pain after meals last 30 min, liver function test?
- Ast 80
- Alt 120
- Alp 900
- Bilt 5
- D:3

- Cholestatic pattern
- Sono: CBD stone